



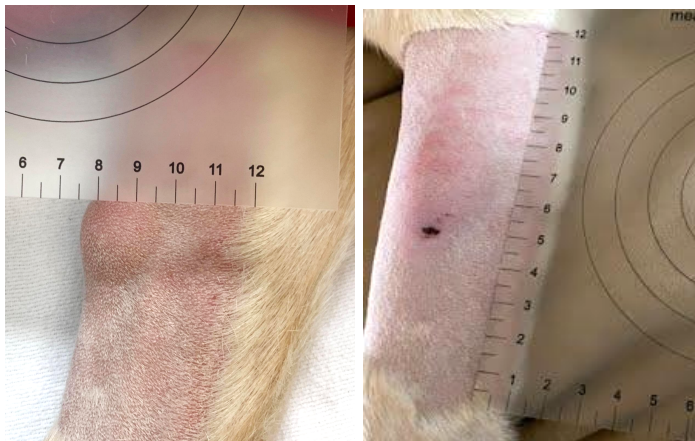
Sam

7yo | Male Neutered | Labrador Retriever | 86 lbs

Patient: 7-year-old 86lb neutered male labrador retriever, Sam, presented with an 18 month history of a 3.8 x 2cm mass on his left forearm. Pathology results of fine needle aspiration performed at the Center for Image Guided Animal Therapy indicate lipoma. Owner was looking to have the mass removed but didn't want to do a surgical resection for a benign mass. Recommendation was made for cryoablation.

Methods: After pre-surgical bloodwork, thoracic radiographs, and FNA, Sam was presented for cryoablation. He was sedated and placed under general anesthesia (isoflurane). Sam was sterilely prepped and draped. A stab incision was made. One 3:20 freeze, 3-minute thaw - 4 minute freeze cycle was performed using the Kubanda Cryotherapy system. No staple or suture was required at the wound site. Sam was discharged with NSAIDs (carprofen) for pain management.

Clinical findings: The owner noted that Sam showed no signs of discomfort and was back to normal energy levels less than 24 hours after the procedure. The owner also noted that the cryoablation procedure site healed well and looked clean with a small scab at the wound site. The owner also noted that the mass was notably smaller and softer to the touch following the procedure. The owner had positive remarks about the entire cryotherapy process and felt comfortable recommending this procedure.



Images show the mass pre treatment (left) and 24 hours post treatment (right)

Conclusion: Cryotherapy stands as a suitable treatment option for necrosis of tissue. As treatment for benign masses are often elective, treatment of such should be done so as to minimize patient discomfort. With similar clinical outcomes in regards to tumor reduction, cryotherapy serves as a competitive alternative to surgical resection. Owner feedback indicates high satisfaction of the cryotherapy procedure and a significant preference for cryotherapy over surgical resection.

Clinical Significance: Cryotherapy has potential for use in benign lipoma, limiting the risks to the patient while reducing size of the mass.